



Today's Date: \_\_\_\_\_

Patient Name: \_\_\_\_\_

Patient DOB: \_\_\_\_\_

SURGEON/DATE

- Paul Cacchillo, MD
  - Patrick Hopen, MD
  - Anthony Lombardo, MD, PhD
  - Michael Orr, MD
  - Ahmar Sajjad, MD
- OD \_\_\_\_\_ OS \_\_\_\_\_

SUBJECTIVE

- Thrilled with visual improvement
- Eye discomfort or pain
- Vision improving
- Vision getting worse
- No complaints
- Other \_\_\_\_\_

- Day 1 after surgery
- 1 week between eyes
- 2-4 weeks after surgery
- 100 day check (refractive)
- \_\_\_\_\_

EYE MEDICATIONS

- OD  none  Pred-Moxi-Nepaf tid x 1 week then bid x 3 weeks
- OS  none  Pred-Moxi-Nepaf tid x 1 week then bid x 3 weeks
- ofloxacin qid
- ofloxacin qid
- Durezol bid
- Durezol bid
- Ilevro qd
- Ilevro qd
- \_\_\_\_\_
- \_\_\_\_\_

EXAMINATION

<b>Vsc</b>	<b>Near Vsc</b>	<b>IOP</b>	<b>REFRACTION</b>
OD 20/____	OD J____	OD ____mmHg	OD _____ 20/____
OS 20/____	OS J____	OS ____mmHg	OS _____ 20/____

CONJUNCTIVA

- OD OS
- white
  - mild injection
  - subconj heme
  - other

CORNEA

- OD OS
- clear
  - arcuate incision(s)
  - edema
  - other

ANTERIOR CHAMBER

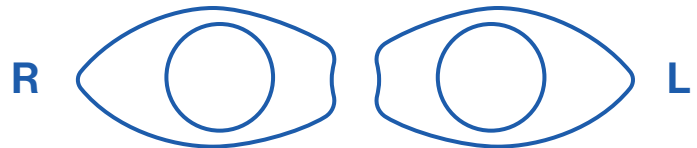
- OD OS
- deep & quiet
  - mild debris
  - mild cell
  - other

IRIS

- OD OS
- pupil round
  - other

IOL

- OD OS
- centered & normal
  - other



POSTERIOR CAPSULE

- OD OS
- clear
  - fibrosis
  - pearls
  - other

RETINA

- OD OS
- unchanged
  - CME
  - other

IMPRESSION

- Normal post-operative course
- Other \_\_\_\_\_

PLAN

- CPM and next visit in \_\_\_\_\_ week(s) / month(s) / year
- Change management \_\_\_\_\_

\_\_\_\_\_  
CO-MANAGING DOCTOR (PLEASE PRINT)

**SUBMIT**

Please fax to (317) 579.7435 or email to referrals@esi-in.com