



Today's Date: \_\_\_\_\_

### SURGEON/DATE

Patient Name: \_\_\_\_\_

- Paul Cacchillo, MD
- Patrick Hopen, MD
- Michael Orr, MD
- Michael Hodkin, MD
- Anthony Lombardo, MD, PhD
- Ahmar Sajjad, MD

Patient DOB: \_\_\_\_\_

OD \_\_\_\_\_ OS \_\_\_\_\_

### SUBJECTIVE

- Thrilled with visual improvement
- Vision improving
- No complaints
- Eye discomfort or pain
- Vision getting worse
- Other \_\_\_\_\_

- Day 1 after surgery
- 1 week between eyes
- 2-4 weeks after surgery
- 100 day check (refractive)
- \_\_\_\_\_

### EYE MEDICATIONS

- OD  none  Pred-Moxi-Nepaf tid x1 week then bid x3 weeks |  ofloxacin qid  Durezol bid  Ilevro qd  \_\_\_\_\_
- OS  none  Pred-Moxi-Nepaf tid x1 week then bid x3 weeks |  ofloxacin qid  Durezol bid  Ilevro qd  \_\_\_\_\_

### EXAMINATION

#### VSC

OD 20/\_\_\_\_\_  
OS 20/\_\_\_\_\_

#### Near VSC

OD J\_\_\_\_\_  
OS J\_\_\_\_\_

#### IOP

OD \_\_\_\_\_mmHg  
OS \_\_\_\_\_mmHg

#### REFRACTION

OD \_\_\_\_\_ 20/\_\_\_\_\_  
OS \_\_\_\_\_ 20/\_\_\_\_\_

#### CONJUNCTIVA

- OD OS
- white
- mild injection
- subconj heme
- other

#### CORNEA

- OD OS
- clear
- arcuate incision(s)
- edema
- other

#### ANTERIOR CHAMBER

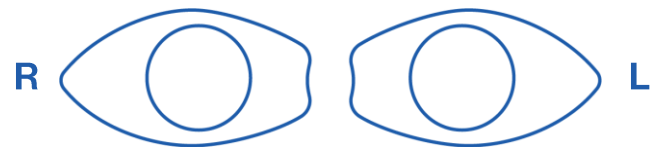
- OD OS
- deep & quiet
- mild debris
- mild cell
- other

#### IRIS

- OD OS
- pupil round
- other

#### IOL

- OD OS
- centered & normal
- other



#### POSTERIOR CAPSULE

- OD OS
- clear
- fibrosis
- pearls
- other

#### RETINA

- OD OS
- unchanged
- CME
- other

### IMPRESSION

- Normal post-operative course
- Other \_\_\_\_\_

### PLAN

- CPM and next visit in \_\_\_\_\_ week(s) / month(s) / year
- Change management \_\_\_\_\_
- \_\_\_\_\_
- \_\_\_\_\_
- \_\_\_\_\_

\_\_\_\_\_  
CO-MANAGING DOCTOR (PLEASE PRINT)

Please fax to 317.579.7435 or email to [referrals@esi-in.com](mailto:referrals@esi-in.com)