



Today's Date: \_\_\_\_\_

Patient Name: \_\_\_\_\_

Patient DOB: \_\_\_\_\_

SURGEON/DATE

- Paul Cacchillo, MD, Michael Orr, MD, Patrick Hopen, MD, Ahmar Sajjad, MD, Anthony Lombardo, MD, PhD, OD, OS

SUBJECTIVE

- Thrilled with visual improvement, Vision improving, No complaints, Eye discomfort or pain, Vision getting worse, Other

- Day 1 after surgery, 1 week between eyes, 2-4 weeks after surgery, 100 day check (refractive)

EYE MEDICATIONS

- OD, OS, Pred-Moxi-Nepaf tid x 1 week then bid x 3 weeks, ofloxacin qid, Durezol bid, Ilevro qd

EXAMINATION

Vsc, Near Vsc, IOP, REFRACTION, OD, OS, mmHg, 20/

CONJUNCTIVA

- OD OS, white, mild injection, subconj heme, other

CORNEA

- OD OS, clear, arcuate incision(s), edema, other

ANTERIOR CHAMBER

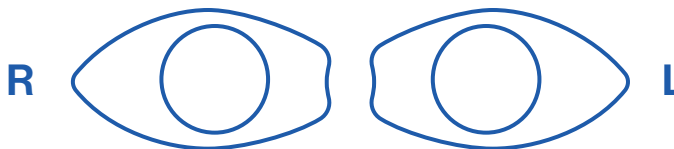
- OD OS, deep & quiet, mild debris, mild cell, other

IRIS

- OD OS, pupil round, other

IOL

- OD OS, centered & normal, other



POSTERIOR CAPSULE

- OD OS, clear, fibrosis, pearls, other

RETINA

- OD OS, unchanged, CME, other

IMPRESSION

- Normal post-operative course, Other

PLAN

- CPM and next visit in week(s) / month(s) / year, Change management

CO-MANAGING DOCTOR (PLEASE PRINT)

Please fax to (317) 579.7435 or email to referrals@esi-in.com