



Today's Date: \_\_\_\_\_

Patient Name: \_\_\_\_\_

Patient DOB: \_\_\_\_\_

SURGEON/DATE

- Paul Cacchillo, MD; Michael Orr, MD; Patrick Hopen, MD; Ahmar Sajjad, MD; Anthony Lombardo, MD, PhD; OD; OS

SUBJECTIVE

- Thrilled with visual improvement; Eye discomfort or pain; Vision improving; Vision getting worse; No complaints; Other

- Day 1 after surgery; 1 week between eyes; 2-4 weeks after surgery; 100 day check (refractive)

EYE MEDICATIONS

- OD none; OS none; Pred-Moxi-Nepaf tid x 1 week then bid x 3 weeks; ofloxacin qid; Durezol bid; Ilevro qd

EXAMINATION

Vsc, Near Vsc, IOP, REFRACTION. OD 20/\_\_\_\_, OS 20/\_\_\_\_. OD J\_\_\_\_, OS J\_\_\_\_. OD \_\_\_\_mmHg, OS \_\_\_\_mmHg. OD \_\_\_\_\_ 20/\_\_\_\_, OS \_\_\_\_\_ 20/\_\_\_\_

CONJUNCTIVA

- OD OS; white; mild injection; subconj heme; other

CORNEA

- OD OS; clear; arcuate incision(s); edema; other

ANTERIOR CHAMBER

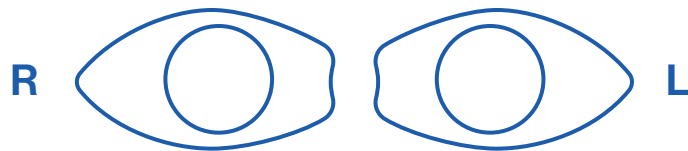
- OD OS; deep & quiet; mild debris; mild cell; other

IRIS

- OD OS; pupil round; other

IOL

- OD OS; centered & normal; other



POSTERIOR CAPSULE

- OD OS; clear; fibrosis; pearls; other

RETINA

- OD OS; unchanged; CME; other

IMPRESSION

- Normal post-operative course; Other

PLAN

- CPM and next visit in \_\_\_\_ week(s) / month(s) / year; Change management

CO-MANAGING DOCTOR (PLEASE PRINT)

CLEAR FORM

SUBMIT

Please fax to (317) 579.7435 or email to referrals@esi-in.com